

## New Advances in the Treatment of the Adult Acquired Flatfoot

Bruce Cohen MD  
OrthoCarolina Foot and Ankle  
Institute

OrthoCarolina



## Acquired Pes Planus

- Pes Planus= Flatfoot
- Components
  - Excessive pronation
  - Heel Valgus
  - Forefoot abduction
  - Flexible vs Rigid



Most Common Cause in Adults  
Posterior Tibial Tendon Insufficiency

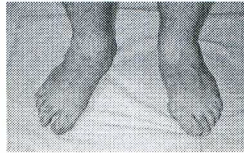
OrthoCarolina



## Acquired Pes Planus

### Clinical Examination

- Heel Valgus
- Single Limb Heel rise
- Test in inversion and eversion
- Swelling, tenderness along PTT
- Fixed deformities
  - Hindfoot Valgus
  - Forefoot varus

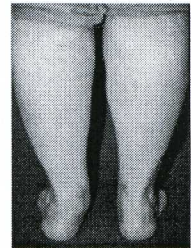


OrthoCarolina



## Posterior Tibial Tendon Insufficiency

- We have come a long way in a short time
  - Case reports: 1979, 1981
  - FDL tendon transfer: 1983
  - First staging: 1985
  - Bony procedures: 1990

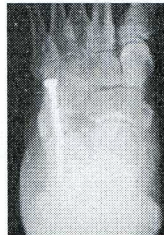

OrthoCarolina



## Posterior Tibial Tendon Insufficiency

- Ideas on pathology and treatment continue to evolve
- We are not there yet!
  - The procedures we are performing today are unlikely to be here in 10 years

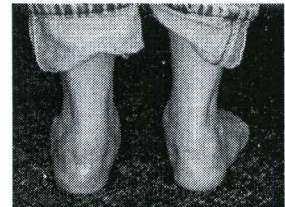


OrthoCarolina



## Surgical Indications/Goals

- Alleviate pain
- Correct deformity
  - Or at least stop progression
- Improve function



*All while minimizing loss of motion or stress on adjacent joints*

OrthoCarolina



