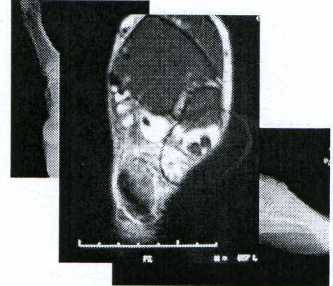


## Managing the Cavovarus Foot

Robert B. Anderson, MD  
Chief, Foot and Ankle Service  
OrthoCarolina  
Carolinas Medical Center  
Charlotte, North Carolina

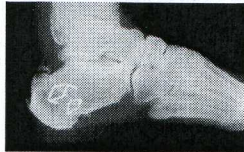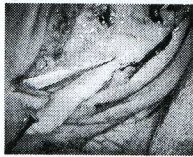### Case Example

- 55 y/o pilot
- Progressive cavovarus
- Fullness over peroneals



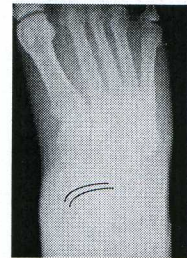### Case Example

- Dwyer
- Peroneal debridement and tenodesis
  - Longus to brevis



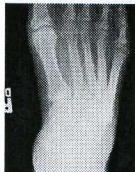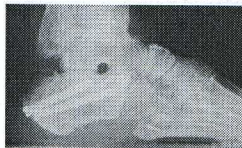### Case Example

- Recurrent problems
  - Persistent/recurrent varus
  - Poor peroneal function



### Case Example

- Revision surgery elsewhere (at my suggestion)
  - Peroneal allograft
  - Redo calcaneal osteotomy



### Case Example

- Not happy
  - Still with lateral overload
  - Complaining of pain 5<sup>th</sup> MT base

